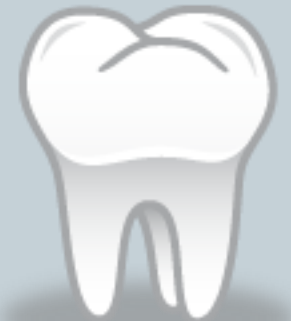


3. PHASE 1: URGENT AND DIAGNOSTIC

36 slides, about 1.5 hour



Treatment Planning Tutorial

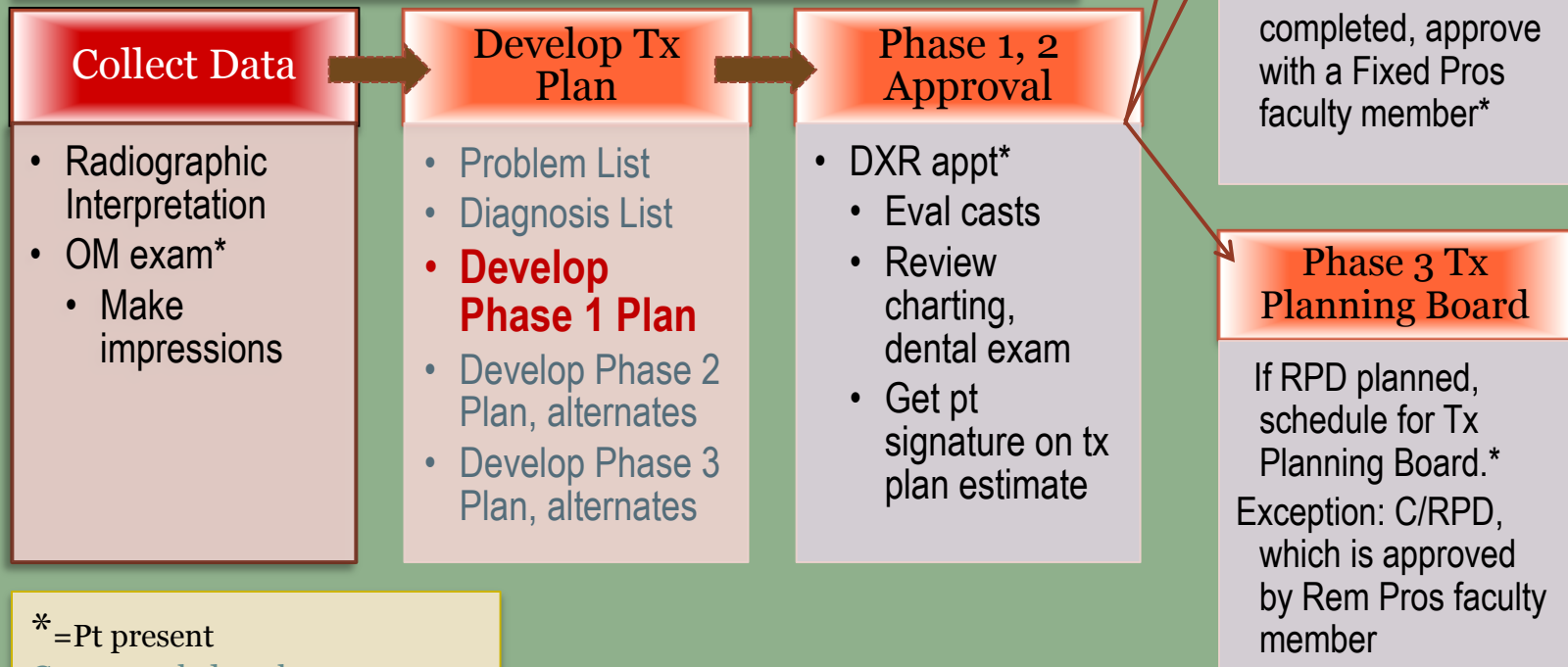
Learning Objectives



1. Recognize Key Decision points in a treatment plan.
2. Give examples of what treatments go into Phase 1,2,3.
3. Be able to explain space infections, what influences their location, the sequence of treatment, and why Ludwig's Angina and Parapharyngeal space infections are a significant threat.
4. List when antibiotics are indicated and when they are not indicated.
5. List and clinically recognize the three treatment planning indications for considering an orthodontic evaluation. Recognize when a case is disease controlled for referral.
6. Define how to determine restorability and list the sequence of restorative and endodontic treatment.

Data Collection → Tx Plan

We've developed a Problem and Diagnosis List, and have some sense for what kind of treatment this patient is interested in both tooth by tooth and overall.
Now we need to start to develop our Treatment Plan



*=Pt present

Gray= work done between appts

Moving from Diagnosis to a Treatment Plan with Phases



**MATCHING DIAGNOSES AND TREATMENTS
DEVELOPING PRIORITIES WITH PATIENT
WHAT GOES IN WHICH PHASE**

Where do you *start*?

3

- **What do you do with this list of problems and diagnoses and patient concerns and who knows what else?**
- How do you get from a disorganized mess to an organized plan...a logical sequence that addresses all problems in the right order at that right time?
- ❖ When it's time to sort out your sock drawer, you dump them all out and inspect them. Then you match them up into pairs, right?

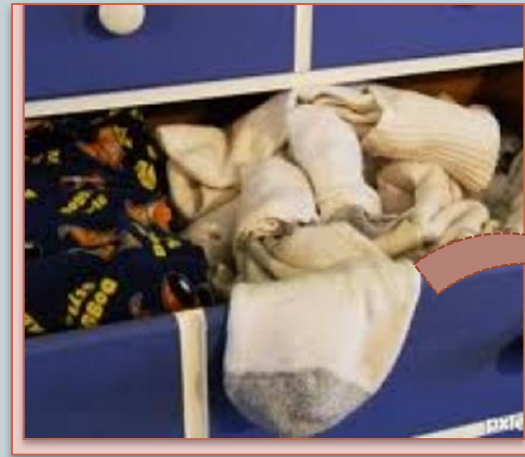


With a treatment plan...

4

- You dump out all the **diagnoses** and in the light of the patient's:
 - Medical concerns
 - Personal preferences
 - Economic resourcesyou plan at least one (usually several) reasonable **treatment options** for each one.
- Looking at all your **socks**, you might sort them by function...maybe Workout socks vs Dress socks vs Crazy color socks, whatever.
- Once you've paired up **diagnoses with treatments**, decide which **phase** each of these treatments belongs in.

Let's try an example. Remember Jill?



Remember Jill's Problem List?

Develop
treatment
plan





5



1. Chief concern identified as “stained teeth” and “spaces between teeth.”
2. Jill’s medical history includes Type 1 diabetes. Last HbA1c was 4 mo ago.
3. Pain “pain with thermal stimuli” in site 19.
4. You also noted:
 - Periodontal problems
 - Caries
 - Missing teeth
 - Occlusal plane problems

Start thinking of possible treatments

6

1. Chief concern identified as “stained teeth” and “spaces between teeth.” 
 2. Jill’s medical history includes Type 1 diabetes. Last HbA1c was 4 mo ago. 
 3. Pain “pain with thermal stimuli” in site 19. 
 4. You also noted: 
 - Periodontal problems
 - Caries
 - Missing teeth
 - Occlusal plane problems
1. Several options.... Porcelain veneers? Orthodontics? Bleaching and direct bonding?
 2. Get current HbA1c
 3. Diagnose pain #19, then go from there to develop tx plan.
 4. Other problems:
 - Perio- D0180, scale, root plane
 - Caries- list needed restorations
 - Missing teeth- options... implants? RPDs?
 - Occlusal plane problems. Wild card! How are we going to manage this??



And focus on the Key Decision Points

Develop
treatment
plan

7

Knowing Jill's problems, you look at her study casts, and start thinking. Some problems don't have any real options...her diabetes is going to be followed up with an HbA1c. But other problems have options, and the **big decisions that are going to determine the overall direction of the case are key decision points**. Examples:

Problem	Possible Treatments	Advantages	Disadvantages
Esthetic Concerns	Porcelain Veneers	Best Esthetics Usually last longer	More expensive Requires tooth prep
	Vital Bleach + Composite Bonding	Less expensive No prep /reversible,	Not as long lasting
Missing 29-32	Implants, fixed partial denture ("bridge")	Very functional Not removable	Expensive, requires surgery Takes up to a year to complete (healing,etc)
	Removable partial denture (RPD)	Less expensive No surgery required Reasonably quick treatment	Less effective chewing, loose Has to be taken out at night. Tends to increase caries, perio risk

What if you can't tell if there's enough space? Or how it might work? To help you see which *might* be possible, you will often do a **diagnostic set-up** in wax.

Back to
Review

But which would work for Jill?

Develop
treatment
plan

8

- You've had a chance to talk to Jill. You know her concerns pretty well, and you have a sense for her **priorities**.
- **BUT...You always want to offer all *feasible* treatment plans!** Maybe she hasn't said she's interested in implants because she's heard they cost \$50,000. If she finds out that here they are only \$10,000, she might be delighted to do that. Maybe not. Maybe she just doesn't want screws in her jaw. You really never know unless you offer all the options with estimates.
- Bottom **line...never assume you know what people can or can't afford.** Every dentist has a story of some poorly dressed patient who paid cash for the highest end treatment plan. (Go read the story of why Stanford University was founded for a useful lesson on *that* idea.) And **never** talk down to a patient.
- After you give Jill some ball-park estimates and talk over the advantages and disadvantages of each treatment, she gives you some **direction** on what she wants.
- Now you can **start matching up problems** with her **preferred** treatments.

Matching up Jill's preferred treatments:

Develop
treatment
plan

9



Medical History
Type 1 diabetes

Verify control with
current HbA1c



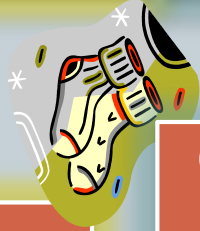Esthetic Concerns
Stained teeth and "spaces
between teeth"

Vital Bleaching
(lighten color)

Direct Bonded
Composites
(close spaces)

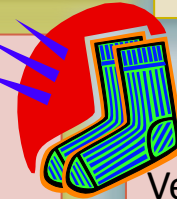


Occlusal plane
#2,3,4
supraerupted



Crown
#3,4
Extract 2

Endodontic
#19- pain with
thermal stimuli



Verify diagnosis,
RCT #19

Dietary counseling
Daily Fluoride x4
Office Fluoride q 3 mo
Xylitol 3x/day

High Caries
CRA=22,
#8,9
2,4



Composites 8,9
Amalgam 2,4

Missing #29-32



Mandibular
RPD

Periodontal
Dx Moderate



D0180
Scl/RP



Matching up Jill's preferred treatments:

Develop treatment plan

9



Medical History
Type 1 diabetes

Verify control with current HbA1c



Esthetic Concerns
Stained teeth and "spaces between teeth"

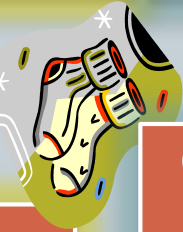Vital Bleaching (lighten color)

Direct Bonded Composites (close spaces)

So which of these do you do first?

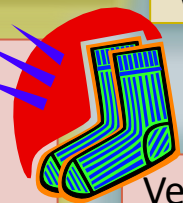


Occlusal plane
#2,3,4 supraerupted



Crown #3,4
Extract 2

Endodontic
#19- pain with thermal stimuli



Verify diagnosis, RCT #19

Oral hygiene counseling
Fluoride x4
Office Fluoride q 3 mo
Xylitol 3x/day



Periodontal
Dx Moderate

High risk
CRA=2
#8,9
2,4

Composites 8,9
Amalgam 2,4

Missing #29-32



Mandibular RPD

D0180
Scl/RP



= Land mine. Be careful!!!

What order do we do these things in?

Develop
treatment
plan

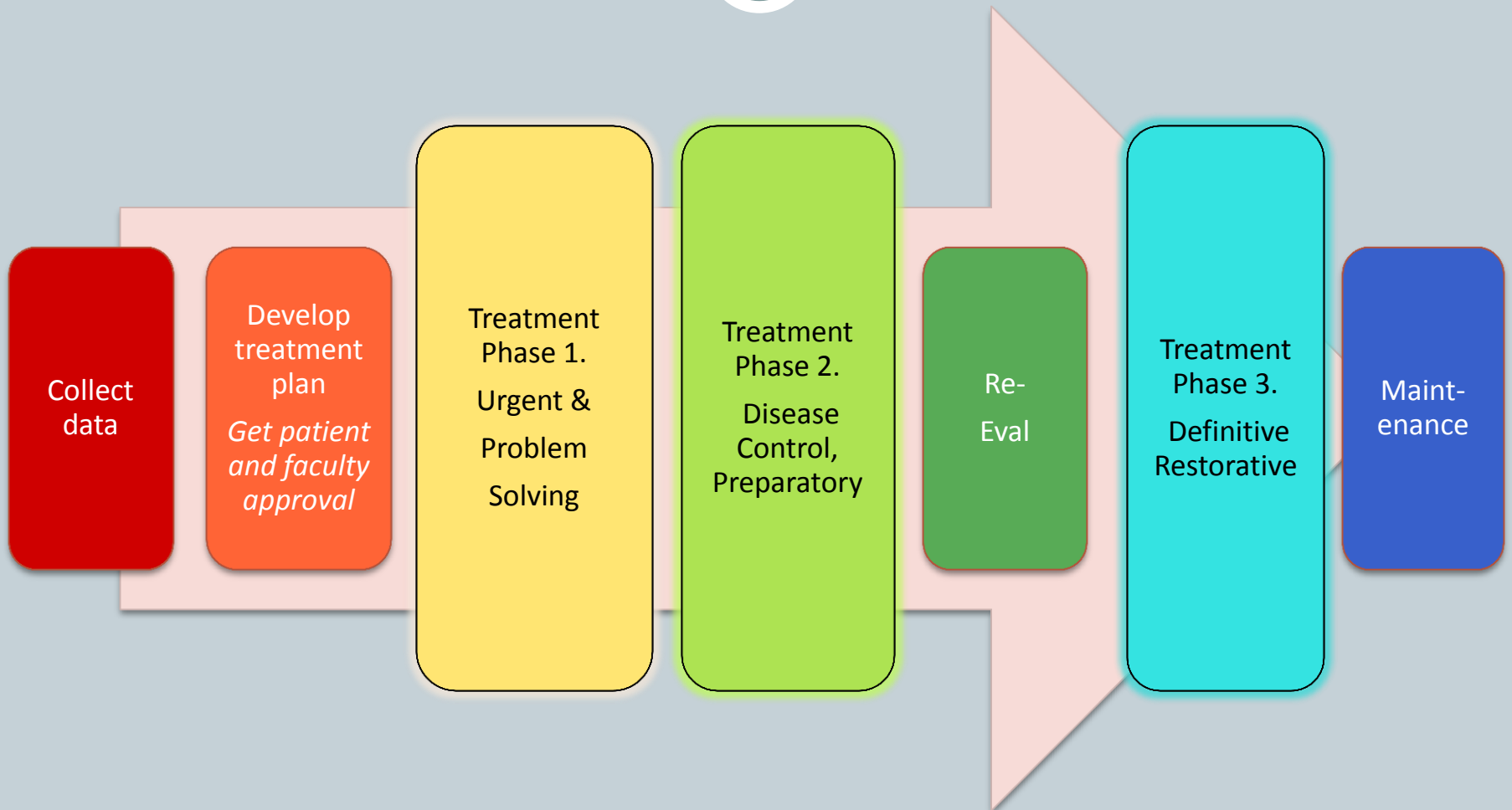
10

It helps to think about what our priorities are...

1. First Priority. Address *urgent* problems, like relieving pain, following up on health concerns, and making sure a suspicious lesion isn't cancer. You also need to get areas of uncertainty cleared up before you can formulate a final treatment plan.
2. Control Disease and Preparatory Treatment. Caries and Periodontal disease need to be controlled before we move on to any other treatment. Any other treatment to prepare the dentition for final rehabilitation treatment is done here.
3. Rehabilitation. Now we can turn to providing restoration of form, function, and esthetics.

Where do those priorities fit with our plan?

11



What fits in each phase:

Develop
treatment
plan

12

Phase 1.

Urgent & Problem Solving

Address urgent problems and answer key questions that will affect the final direction of treatment plan.

Urgent problems:

Answer medical questions,
Relieve pain, Biopsy
suspicious lesions,
Provisional replacement of
missing anterior teeth

Sample Key Questions:

Is this tooth restorable?
Does endo need to be
redone? Can an implant be
placed there? Should we
do ortho first?

Phase 2.

Disease Control

Control disease and prepare patient for Phase 3. Usually does not leave pt worse if do not progress to Phase 3.

Ortho- arrange teeth to prepare for prosthetic care.

Endo- treat pulpal pathosis

Perio- treat perio disease

Surgery- remove hopeless teeth, place implants, shape bone for denture placement

Caries- Control disease with diet counseling, fluoride, etc. Operative to restore carious lesions.

Phase 3.

Definitive Restorative

Restore form, function, and esthetics.

Ortho- definitive care

Endo- when done for restorative reasons

Perio- Esthetic, mucogingival, or changing ridge shape in conjunction with prosthetic treatment.

Fixed Pros- Crowns, fixed partial dentures

Removable Pros- RPD, complete dentures.

Back to
Review

Now start sorting!!

Develop
treatment
plan

13

So which category-which bin- do you throw each of Jill's treatments into?



Sort the socks by function:

Develop
treatment
plan

14

Medical History
Type 1 diabetes



Verify control with
current HbA1c

Endodontic
#19- pain with
thermal stimuli



Verify diagnosis,
RCT #19

Phase 1.
Urgent & Diagnostic

Esthetic Concerns
Stained teeth and
"spaces"



Vital Bleaching
(lighten color)

Direct Bonded
Composites
(close spaces)



Composites 8,9
Amalgam 2,4

Caries
CRA=22
#8,9
2,4

Dietary counseling
Daily Fluoride x4
Office Fluoride q 3 mo
Xylitol 3x/day


Periodontal
Dx Moderate



D0180
Scl/RP

Phase 2.
Disease Control,
Preparatory

Occlusal plane
#2,3,4
supraerupted



Crown
#3,4
Extract 2

Missing #29-32



Mandibular
RPD

Phase 3.
Rehabilitation

But wait...

Develop
treatment
plan

15

- You're probably thinking "since when are stained teeth and spaces part of Disease Control?" and you'd be right.
- **But-** That was her chief concern! If we don't address that fairly soon, we aren't being responsive to her needs.

Besides, since we're going to be doing composites on #8 and 9, we would need to do the vital bleaching first (so we would be selecting the correct shade, right?) so why not go ahead and meet her esthetic needs? A happy patient refers her friends...

Begin with the end in mind.

Develop
treatment
plan


16

The complexity comes when you learn how many options there are to treat any particular diagnosis.

Take a look at Jill:

- Her carious lesions in #2, 4 could be restored with either composite or amalgam. Which is best? *Depends.*
- *But wait*, didn't you say you're going to extract #2 because it's supraerupted and there isn't enough space for an RPD? Or crown it to make it shorter so the RPD will fit? *Yep.*
- You need to figure all that out before you start drilling away on anything.
- Occlusion always has to be part of the plan!

“Boom”



Treatment *before* Treatment Planning Board

17

- But there are going to be times when you can't get a Treatment Planning Board appointment for a few weeks and you're going to ask "**can I start on the directs** while I'm waiting for Treatment Planning Board?"
- Well, you can, **if you know the difference** between directs that will be done in any treatment plan, and those that depend on which Phase 3 plan is chosen.
- So- **do your homework**. In your Phase 2 Treatment Plan (which will be approved at DXR) sequence it so that you know which **direct restorations will not be affected** by decisions made at Treatment Planning Board.

Phase 1: Urgent and Problem Solving



- Urgent Treatment:**
- **Space Infections**
 - **Acute Periodontal Infections**

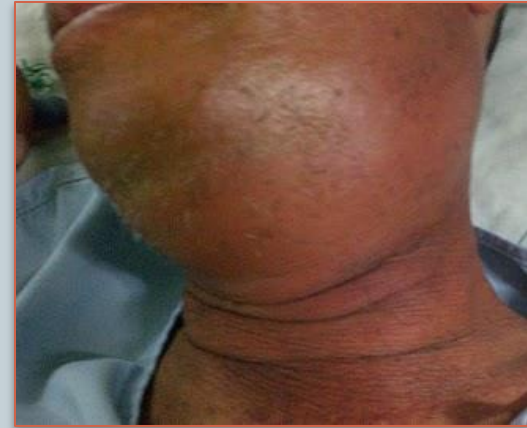- Problem Solving:**
- **Medical**
 - **Orthodontics**
 - **Implants**
 - **Periodontics**
 - **Endodontics**
 - **Restorability**

Phase 1. Urgent and Problem Solving

Phase 1
Urgent

18

- **Let's start with urgent.** It's easy to define: Pain. Bleeding. Swelling. Infections. But also giving a patient a front tooth so they can go to work can be urgent.
- We've covered **pain** already, and you will learn options for that **missing front tooth** in Prosthodontics. **Bleeding** (like from trauma) will be handled in Oral Surgery.
- What about **swelling**? *Usually swelling means an infection.*



Space Infections

General concepts on management:

1. Once the infection is out into the **facial spaces**, just **starting endo or removing the tooth is not enough**. First, the space infection must be managed, then the original problem (endo, 3rd molar, etc) is addressed.
2. **"Pus must pass"** - an incision must be made into the infected area and a drain put in.
3. Generally, these should be managed by an Oral and Maxillofacial Surgeon. Make friends with one- you can really learn a lot from them

Red Flags

19

- Any of these symptoms should make you sit up and pay attention!
 - **Fever**
 - **Swelling**
 - **Trouble swallowing**
 - **Trouble breathing**
 - **Trismus**
- If you can't find the origin of the problem, or are not sure you have solved the problem, **get the patient to someone who can** (ie an Oral Surgeon)!
- **Follow these patients!** Call them even if they don't come back to the clinic.



Peterson's Steps of Management:

1. Determine severity

- Location
 - Low: Buccal, infraorbital vestibular, subperiosteal
 - Mod: Masticatory spaces- Submasseteric, pterygomand, Sup Deep Tarp
 - Peri-mandibular spaces- submandibular, submental, sublingual
 - Severe: Lat pharyng, retropharyng, danger space, cavernous sinus thromb

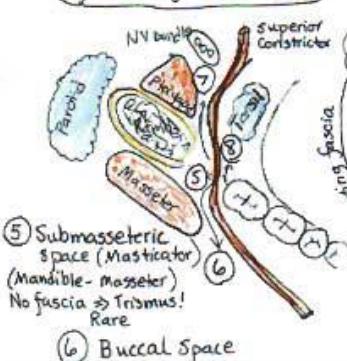
• Rate of progression - faster = more dangerous

2. Eval Host Defenses - Systemic reserve; metabolic problems: diabetes, ETOH, CA
3. Determine setting of care: Hospitalize if T>101, dehydration, airway comp.
4. Treat Surgically - early is better - "pus must pass"
5. Support medically
6. Choose antibiotic:
 - 1. PenVK 500mg qid x 7d
 - 2. Clindamycin 300mg qid
 Penicillin allergic:
 - 1. Clindamycin 300mg qid
 - 2. Moxifloxacin 400mg qd
7. Give antibiotic correctly
8. Evaluate often with fever gone, no drainage

10 Palatal abscess

9 Space of the Body of the Mandible

Infections of Lower 3rds



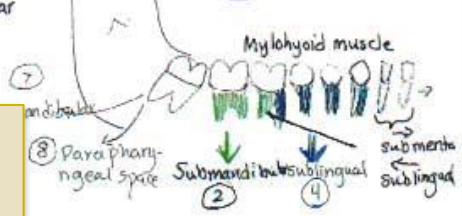
8 Parapharyngeal Space (Sup. Constrictor - pharyngeal mucosa) Treat aggressively ↑

7 Pterygomandibular Space (Mandible - Med Pterygid m)

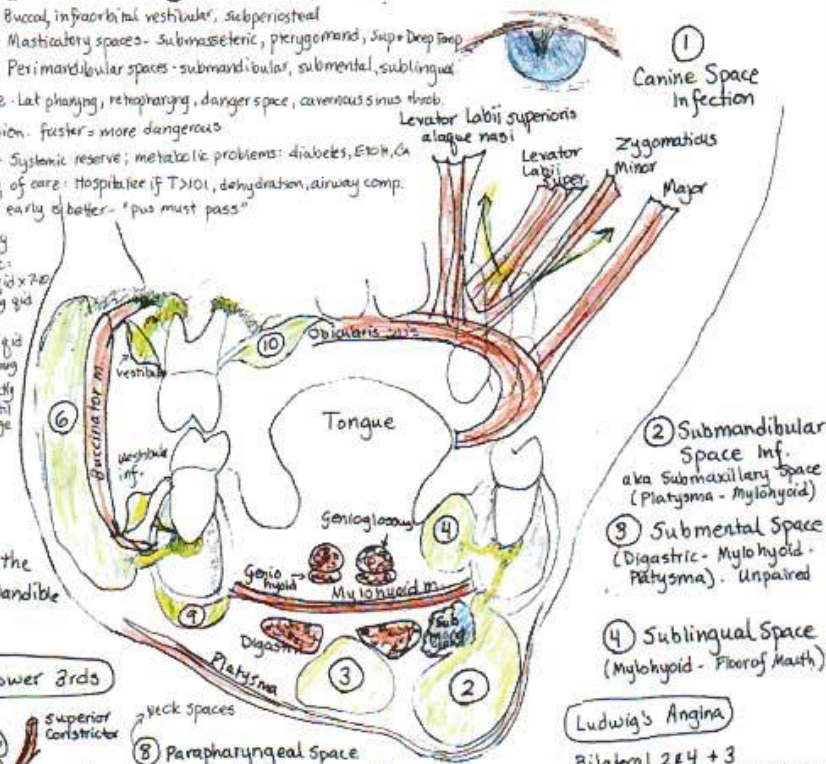
2 Submandibular Space

Ludwig's Angina
Bilateral 2#4 + 3
- Brawny edema, elevated tongue
Little to no pus

Lingual Mandibular Spaces



Space Infections



There's a copy of this on the class website.
Print it out so you can read it.
You may need it some day...

Applied Head and Neck

Let's put your Head and Neck Anatomy classes to practical use!

This is a drawing I made to help visualize and remember space infections.

Key concepts:

- Infections usually start from the apex of an abscessed tooth or pericoronitis on a 3rd molar.

- Drainage direction and structure location (like muscle origin and insertion) determine which space is infected.

- Some of the spaces are connected - infection can flow around. Life-threatening:

Ludwig's Angina is bilaterally submental, sublingual, and submandibular, leaving no room for the tongue but into the airway.

Parapharyngeal space can go into the neck spaces which blocks off the airway.

Both of these can compromise the airway and are life-threatening.

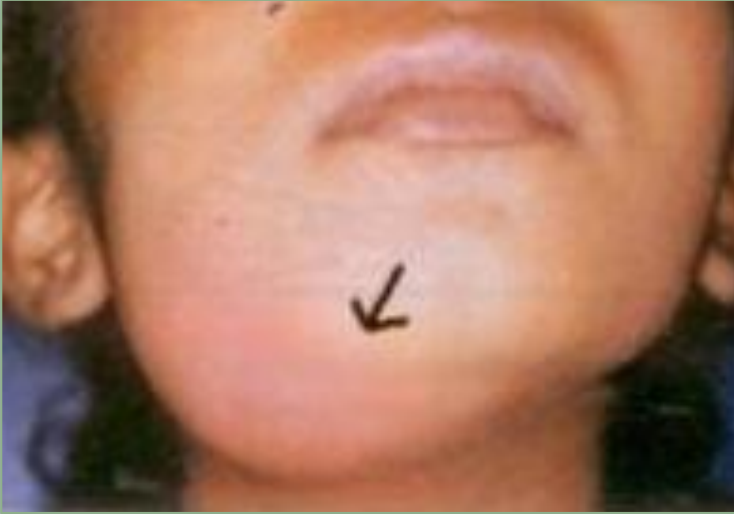- There are only 10 of these spaces, and if you think about where the muscles are and how they relate to the teeth, you can have a pretty good guess of which space is which.

Back to Review

Case 1. Suzanne

Phase 1
Urgent

21



This patient remembers having a bad toothache “a month or two ago” and then a dull ache that started about 5 days ago. Two days ago she woke up with a swelling which has rapidly worsened to this condition. The swelling is relatively hard with a soft fluctuant central area. She has a temp of 101.2.

- Which space is this most likely to be?
 - a Submandibular
 - b Submental
 - c Sublingual
- Which tooth is most likely to be the origin?
 - a #26
 - b #29
 - c #31

Indications for Antibiotics

Phase 1
Urgent

22

Not indicated:	Indicated for:
Pulpitis	Persistent infections
Necrotic pulp + radiolucency Apical periodontitis Sinus tract	Systemic illness: Temp >100, Malaise, Lymphadenopathy
Localized, fluctuant swelling (may need to be drained, but still may not need AB's)	Progressive infection: Trismus, Cellulitis, Increasing swelling
"I don't have time to take that tooth out or start a root canal today, so I'll give you this to hold you till I can get you in."	Osteomyelitis (OMFS referral!)
"I'd feel more comfortable if you took some antibiotics"	
The patient wants a prescription for <i>something</i> ...	

- While we're talking about this, let's make sure you understand when antibiotics work and **when they *don't* work.**
- Antibiotics are still hugely overprescribed for many things, dentistry among them.
- **The idea that antibiotics will help control pain in pulpitis or periapical inflammation has been disproven** in study after study but many dentists still stubbornly cling to the belief, even when confronted with the evidence.

"Don't be that guy"

Back to
Review


Understanding Pain Management

Phase 1
Urgent

23

- You will take your **Pharmacology** course in the Junior year, but in the mean time, here is the basic plan for dealing with pain.
 - Over the counter medications are quite effective for mild-moderate pain. We've got research. Reassure your patient-confidence works.
 - Ibuprofen is dose-dependant. It is a good **pain reliever** at lower doses:
 - 400 mg every 4 hours (q4h)
 - 600 mg every 6 hours (qid)
- But for it to be **anti-inflammatory**, it needs to be the highest dose:
- 800 mg every 8 hours (tid)

And Ibuprofen has a **very slow onset** of relief (40 minutes). Start pts on it *before* anesthetic wears off, and have them **take it by the clock** instead of waiting until they hurt.




Mild

- Aspirin
- Tylenol
- Ibuprofen 400mg, 600 mg



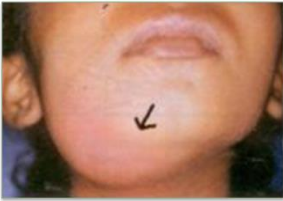Moderate

- Ibuprofen 800 mg three times a day (tid) by the clock
- Consider adding narcotics



Severe

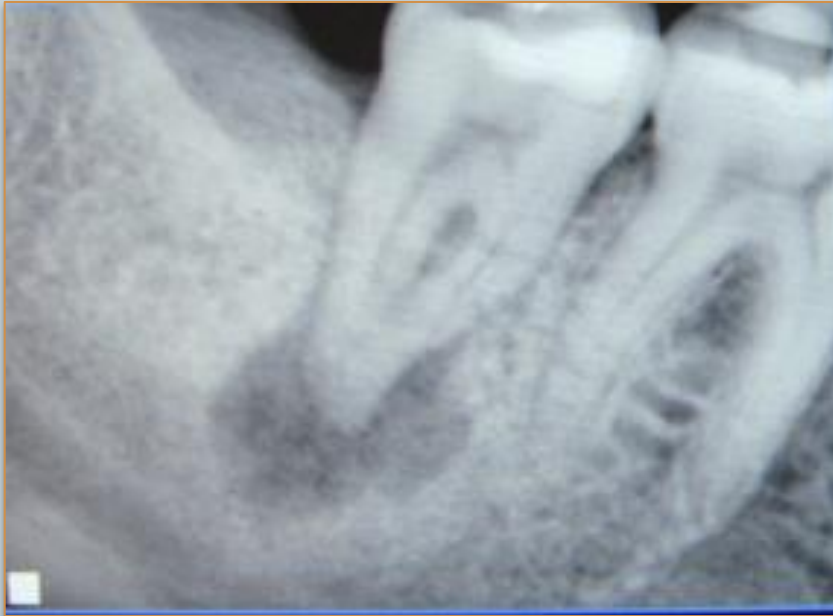- Mod + breakthrough med:
- Narcotics q4h as needed



Case 1. Suzanne

Phase 1
Urgent

24



Suzanne is an otherwise healthy patient with no allergies to any medications.

You take a radiograph and see this image. The patient wishes to save the tooth. What do you do?

- a** Start a non-surgical root canal treatment (endo) and drain through the access, start antibiotics.
- b** Incise and drain the abscess surgically, place a drain, and when the acute infection is resolved start endo.
- c** Incise and drain the abscess surgically, place a drain and start endo the same day to remove the source of the infection.

After the procedure, what will you prescribe/recommend?

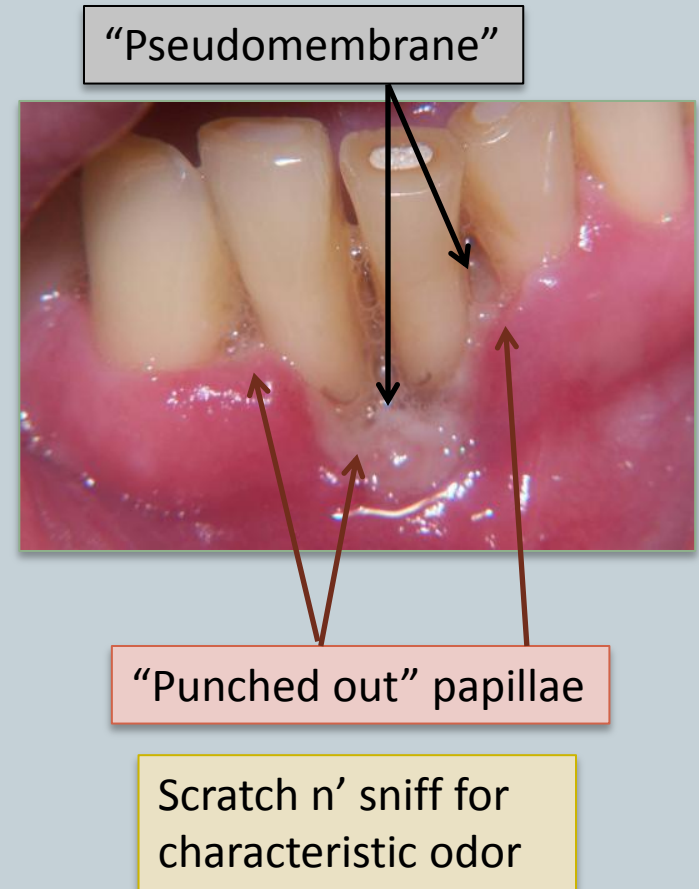
- a** Antibiotics
- b** Over the counter pain medications
- c** Narcotic pain medications

Acute Periodontal Infections

Phase 1
Urgent

25

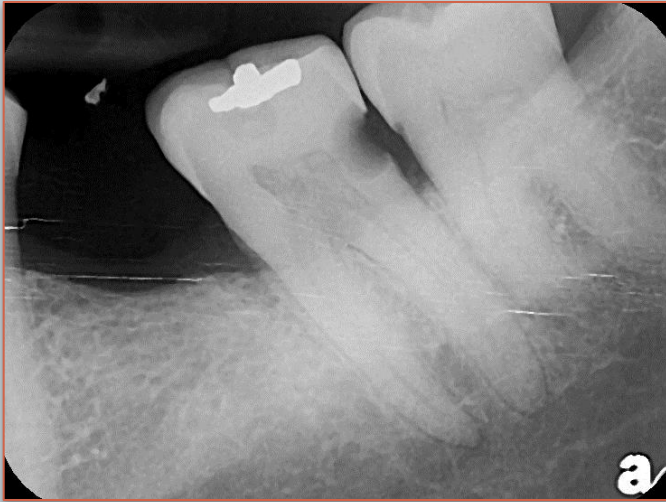- Remember learning about an **acute periodontal abscess**? There is another kind of periodontal disease that is quite painful.
- It used to be called “**trench mouth**” because it was common in the trenches in WWI. They thought it was an infectious disease, but really it was only because in the trenches they were getting shot at so they were stressed out and nutrition was poor.
- It was common again in the early days of HIV before current medications were available. Now you can see it on college campuses during finals (cold pizza, anyone?) or boot camps or in anyone who is stressed. It’s called **NUP or Necrotizing Ulcerative Periodontitis**.
- The bacteria invade the gingival papilla causing rapid loss of papilla, bone, and attachment mechanism. It has a classic grayish slimy “pseudomembrane” and “punched out” papillae and a really vile smell that you will never forget once you have gotten a whiff. Tends to attack first molars and mandibular anterior molars.
- Treatment? Sleep, good nutrition, and good oral hygiene as well as antibiotics.



Phase 1. Problem Solving

Phase 1
Problem
Solving

26



Let's look at #19

Let's assume that we would really like to keep #19 for the treatment plan. So what are you thinking....

1. Does it need endo?
2. Is it restorable?

- **Problem solving** is a harder concept, and we need to spend some time on this one.
- Let's look at the kinds of questions we might be asking:
 - Is that soft tissue lesion anything we should worry about?
 - Is this tooth restorable?
 - Does the endo need to be redone before I put a crown on it?
 - Can I plan implants for that space? How many will I need?
 - Should we do ortho first?

Answer Medical Questions

Phase 1
Problem
Solving

27

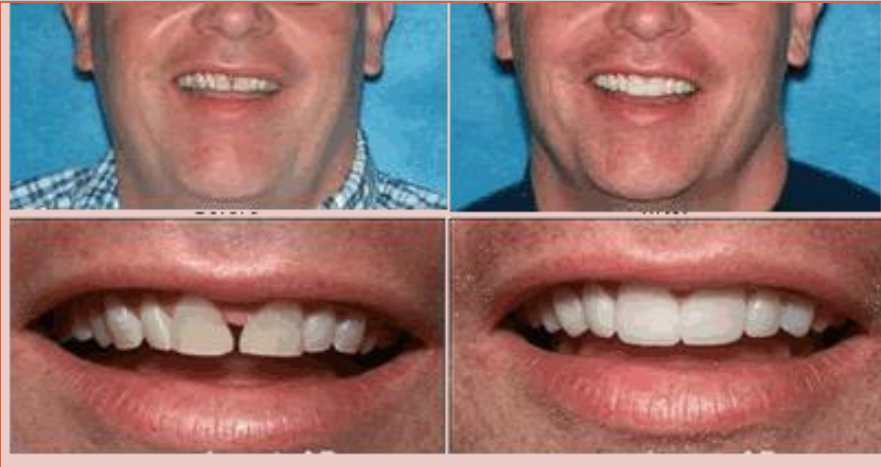- As you were taught in Oral Medicine, **you** are the best trained person to know the parameters for dental care.
- But if there are issues in the medical history that require clarification or testing, the time to get the answers you need is before you start treatment.



Specialty Consults: Orthodontics

Phase 1
Problem
Solving

28



This patient had a single large space between his centrals partly closed with composite. Imagine how BIG these teeth would be if veneers were placed on them in this position! But after ortho, the space was shared and the teeth could be sized normally for a nice result.

- Ortho- it's not just for kids any more!
- It can be quite helpful in setting up restorative care.
- You will learn more in your ortho class, but for now, consider ortho when dealing with:
 1. **Space or crowding** issues if you're doing Fixed Pros
 2. **Implants!** Once they are in, you can't move them, or the teeth around them. Think of ortho before you put in implants!

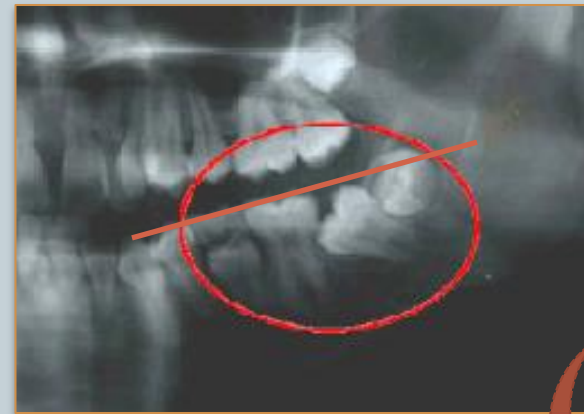Orthodontic Adjunctive Care: Molar Uprighting

Phase 1
Problem
Solving

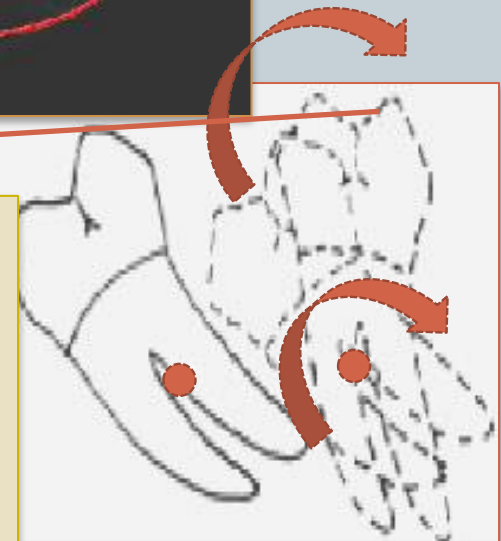29

3. Problem: Tipped molar. Sometimes you want to use for an FPD abutment, but you can't prepare it correctly if it's tipped too far- you'll see why in Fixed Pros lab.

- ❖ But notice the **center of rotation**- a point in the center of the root.
- ❖ This usually means the crown rotates **above the plane of occlusion**- keep that in mind for your planning.
- ❖ Finally, ortho is NOT a fairy-dust answer: you can't just say "oh, I'll move those teeth" without knowing that it is *feasible*. You have to move teeth where there is bone, for example. It's harder than it looks....



In this case, the tooth is well below the plane of occlusion, so after uprighting it will probably only need minor adjustment. But if it was at or above the plane, it would end up well above it and maybe unusable.



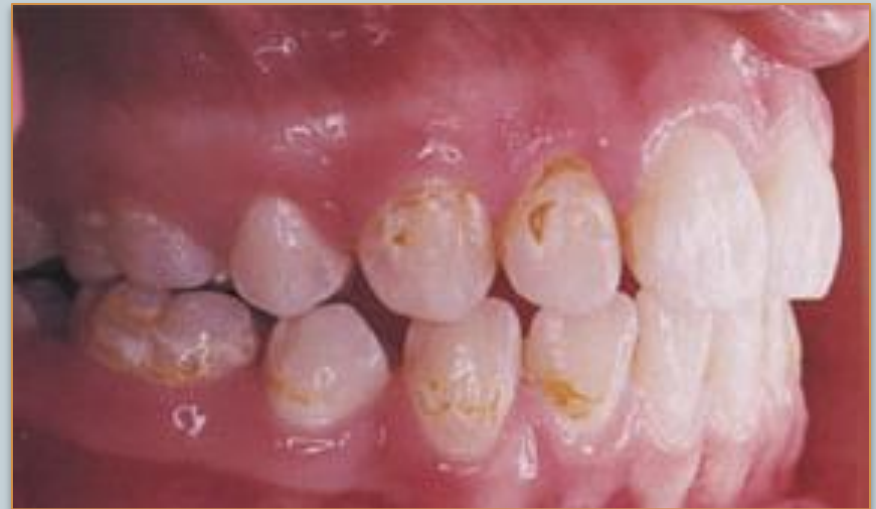Adjunctive Orthodontic Care

Phase 1
Problem
Solving

30

BUT

- Before an orthodontist will consider the case, they will ask the referring dentist two questions:
 - Is the patient **caries active**?
 - Does the patient have **active perio disease**?
- Why? Because **Ortho treatment will aggravate both of these diseases** and the patient will be *worse* off than if they had not had the treatment.
- You want to have a good working relationship with your referring orthodontists **to get these diseases under control before placing appliances.**



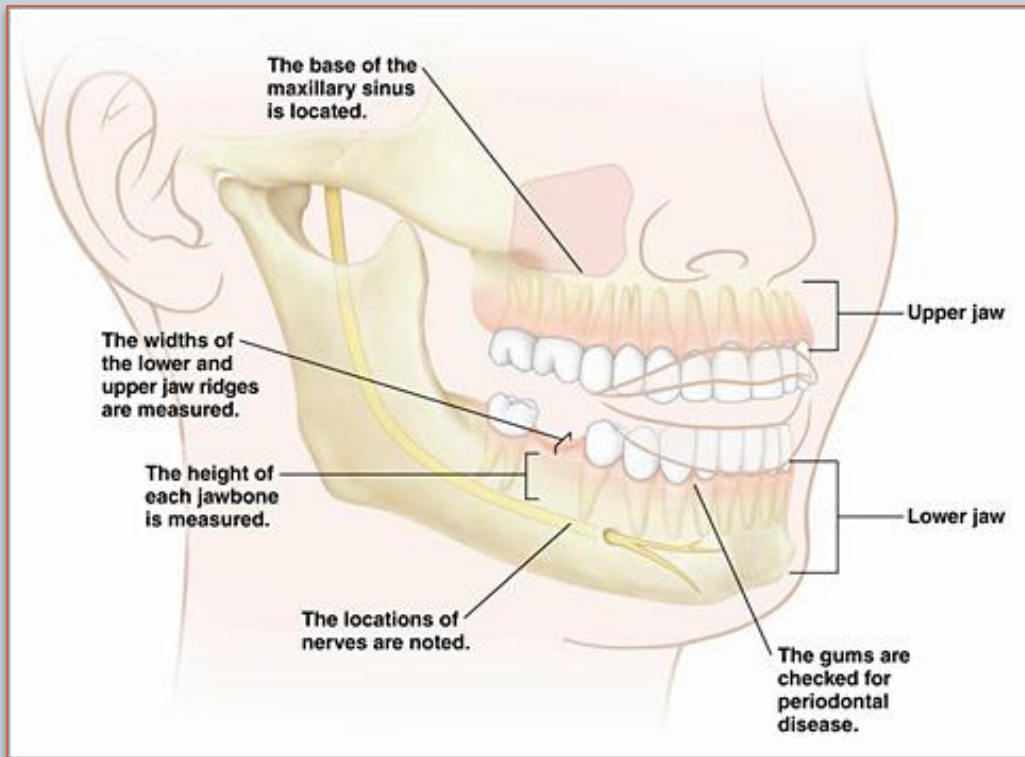
Note the pattern of caries and white spot lesions around areas where the brackets were bonded, where the *S.Mutans* laden plaque builds up. This is not the esthetic result orthodontists want to show on their websites! It's much harder to brush and floss around ortho appliances, too, so perio disease is a consideration.

Back to
Review

Implants

Phase 1
Problem
Solving

31



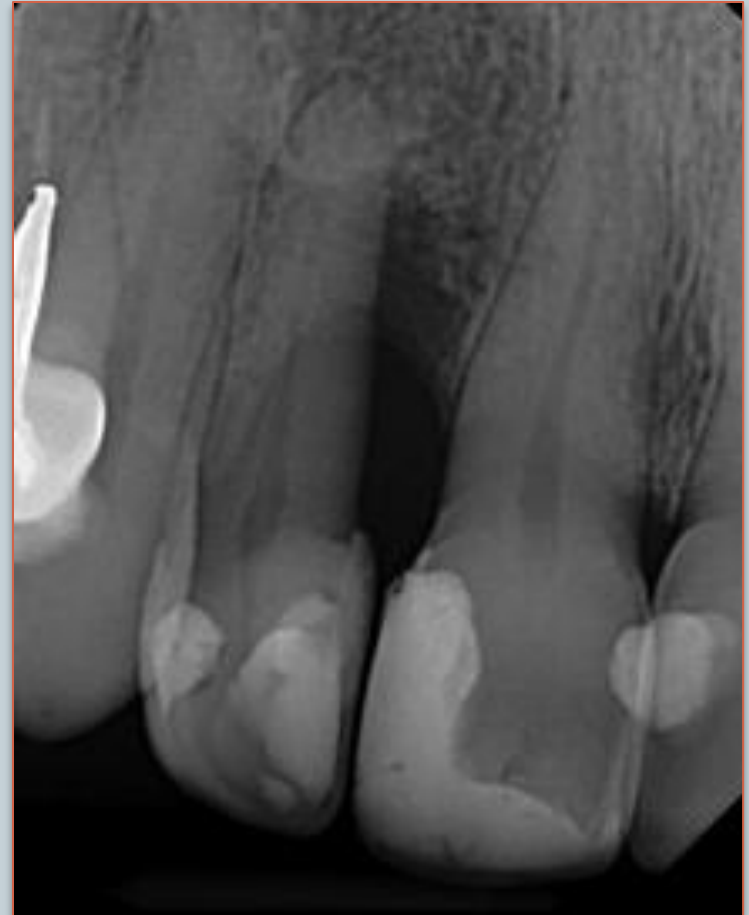- We will talk more about implants in a later tutorial, but for now let's say the patient is interested. Are implants a *feasible* option?
- The major questions are:
 - Is there enough bone to support an implant?
 - Is there enough space for the crown /FPD?
 - Is the patient a good candidate health-wise and psychologically?
- You will go through patient services, who will assign them to one of three departments for an evaluation. (Oral Surgery, Perio, GPR)

Periodontics

Phase 1
Problem
Solving

32

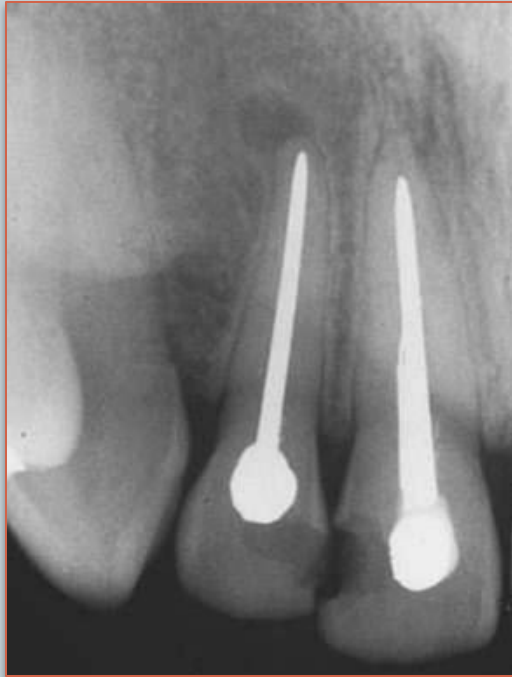- The question- Is tooth #7 savable periodontally? If so, what would be required?
- This patient would require a **D0180** rather than just a prophyl, right?
- Your perio exam will look at each tooth on it's own, but also keep in mind your overall treatment plan, and what role this tooth might play.
- Are you thinking of using that tooth to support an FPD? An RPD? You might run that past the periodontist as part of the overall consideration.



Endodontics

Phase 1
Problem
Solving

33



What if you are thinking of putting crowns on these teeth for esthetics? Would you need to redo these endo txs first? Would it be smart to do that? I'd sure **ask an endodontist.**

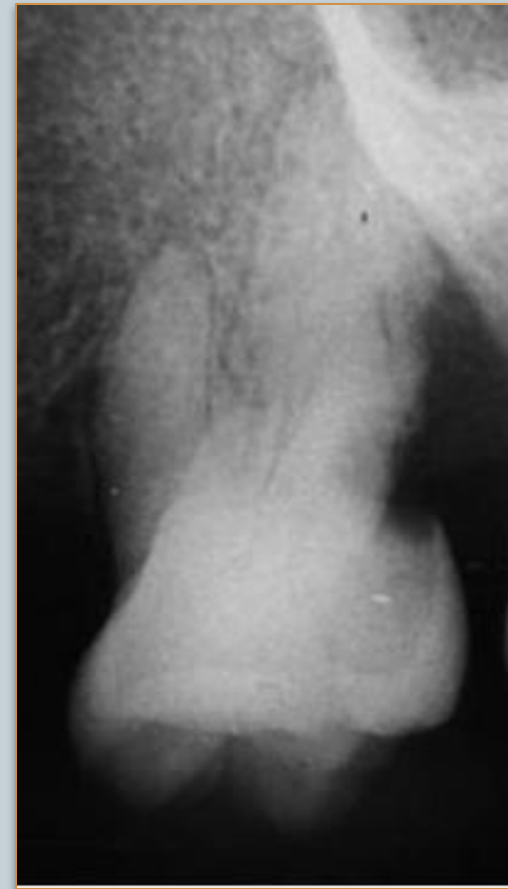
- You've already learned how to evaluate a tooth endodontically—generally do your own diagnosis before you refer.
- But what if the tooth is already endodontically treated, but doesn't look right radiographically or clinically? **Best answer is an endo consult.**
- What if an endo treated tooth still has **not been restored correctly**? If the endo fill itself (the gutta percha) has been exposed to saliva for more than 3-4 weeks, consider redoing the endo. The oral bacteria have contaminated the endo fill and it may fail.
- Again, tell the Endodontist your restorative plan so they can give you the best advice!

Is this tooth restorable?

Phase 1
Problem
Solving

34

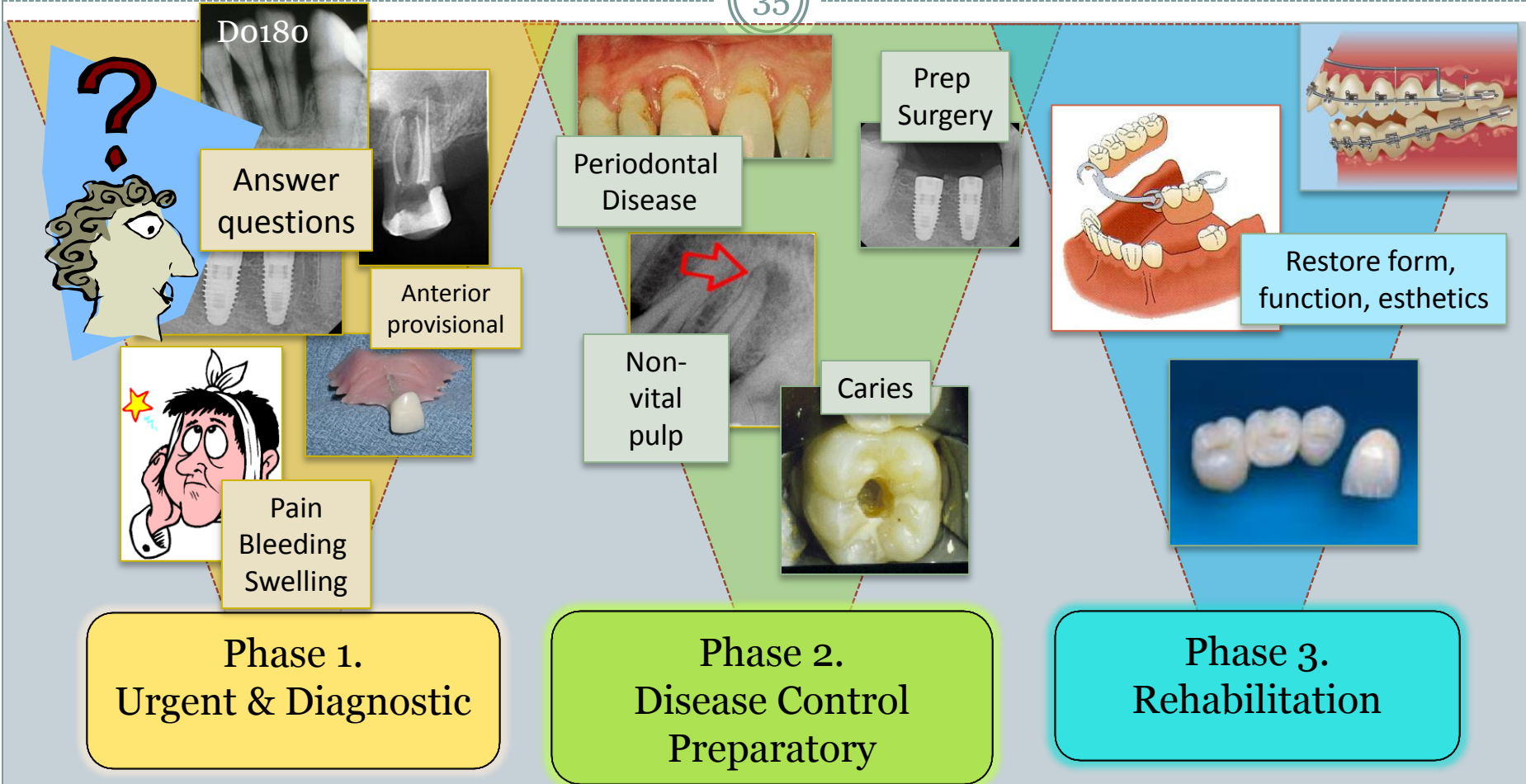
- Let's get to the **bottom line**: You generally can't tell from a radiograph or even visually if a tooth is restorable or not if it's borderline.
- **What works?** Remove the caries and see if you can get a **matrix band** on it. If you can get a matrix band on it, then you can restore it.
- **Crucial concept**: you must determine if the tooth is restorable *before* you do the endo. Why?
 1. Let's say you don't, and after the endo you find out the tooth is NOT restorable! Ouch! (Pull out your checkbook...) Planning keeps you from the embarrassing position of taking out a tooth you just did a root canal on.
 2. A good restoration helps hold on the rubber dam retainer.
 3. With a good restoration in place, you can better control the sodium hypochlorite (bleach) that's used to irrigate the root canal space- it won't leak out through the deep cavity if there's a nice restoration in it.



Back to
Review

Summary: Overview of Phases







35



Review of Learning Objectives

36

If you have trouble with any of these, click on the link. Some cover several pages before the Return to Review button appears. Be sure you know all the terms in **blue** or **red** in the tutorial.

1. Be able to recognize Key Decision points in a treatment plan. 
2. Give examples of what treatments go into Phase 1,2,3. 
3. Be able to explain space infections, what influences their location, the sequence of treatment, and why Ludwig's Angina and Parapharyngeal space infections are a significant threat. 
4. List when antibiotics are indicated and when they are not indicated. 
5. List and clinically recognize the three treatment planning indications for considering an orthodontic evaluation. Recognize when a case is disease controlled for referral 
6. Define how to determine restorability and list the sequence of restorative and endodontic treatment. 

Now that you know the basics...



- **Read Chapter 3 pg 53-65** (before occlusion): Developing the Treatment Plan
- **Read Chapter 6 pg 113-135**: Acute Phase of Treatment. Gives you a very good overview of how to handle an emergency patient start to finish. Also has a good review of the pain material we covered last semester, but in more detail.

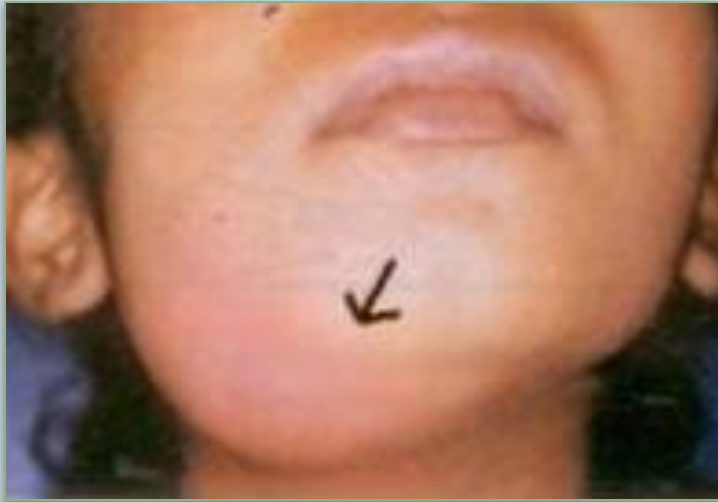Nice work!



St James Church
Chipping Campden



Case 1: You chose a “Submandibular Space”



- Correct!
- You probably noticed that the swelling is on one side only (eliminating the unpaired Submental space which would be right in the middle) and that it is under the Mylohyoid muscle.
- Nice work!

Return

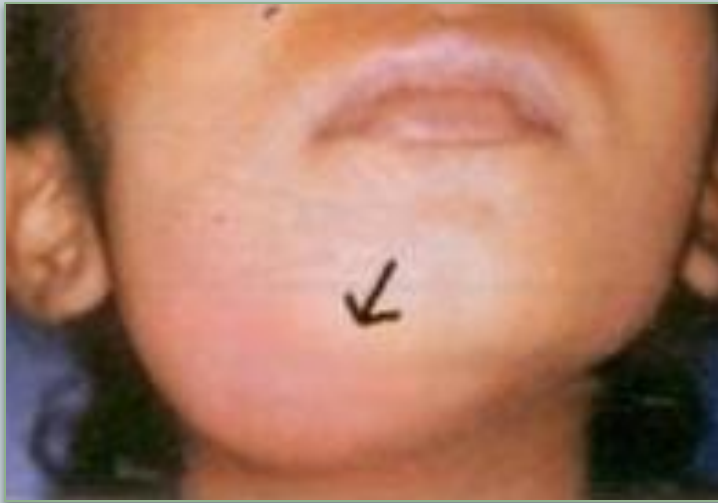Case 1: You chose b “Submental Space”



- Probably not.
- Check the diagram and try again!

Return

Case 1: You chose c “Sublingual space”



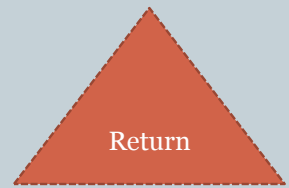
- Probably not
- Check the diagram and try again!

Return

Case 1: You chose a “#26”



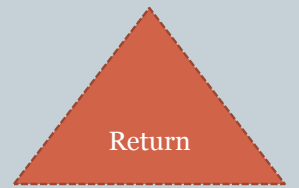
- Probably not...
- Check the diagram and try again!

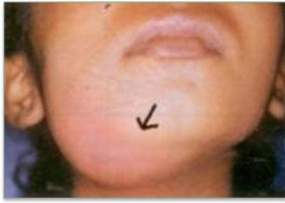

Case 1: You chose b “#29”

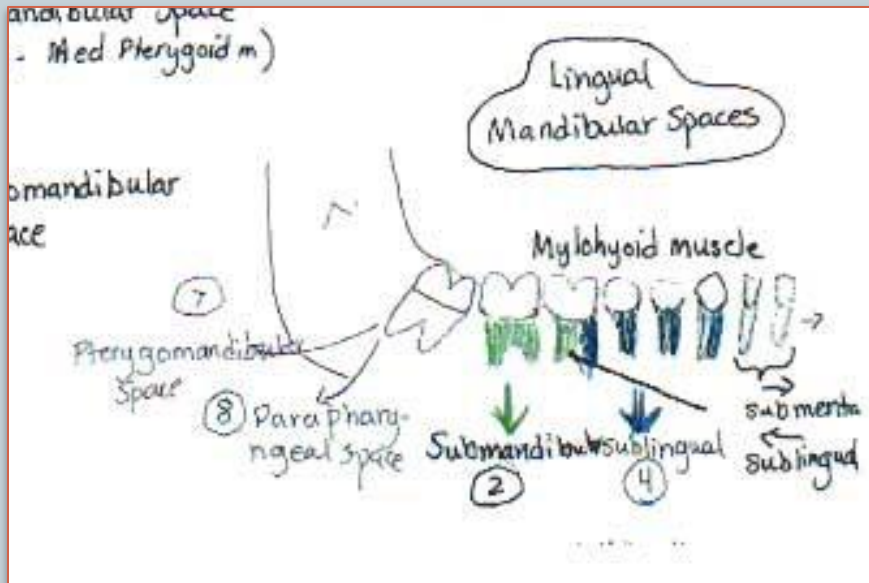


- Probably not.
- Check the diagram and try again!



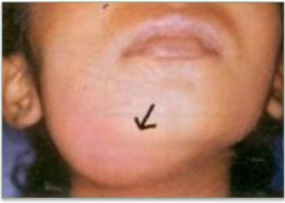

Case 1: You chose c “#31”

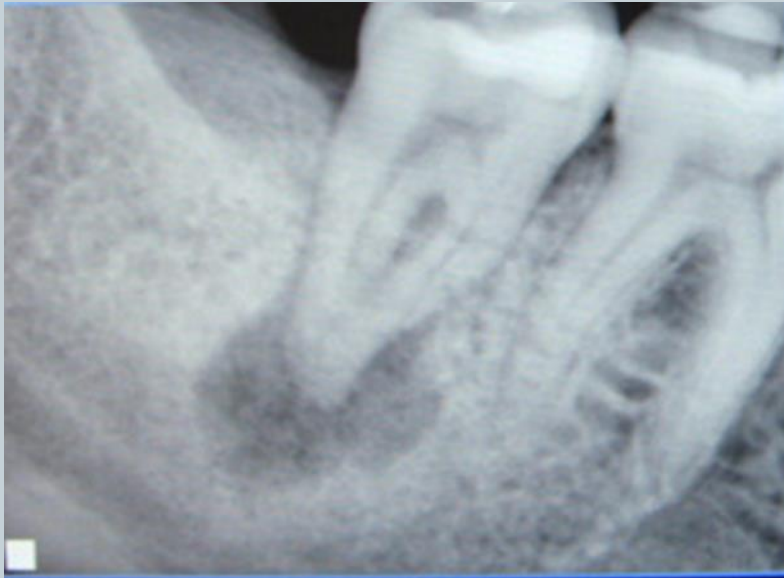

- Correct!
- You probably noted that the most likely tooth to be below the mylohyoid insertion is a second molar, so #31 is a likely option.
- Nice work!

Return

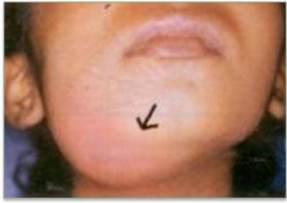

Case 1. You chose a- Endo

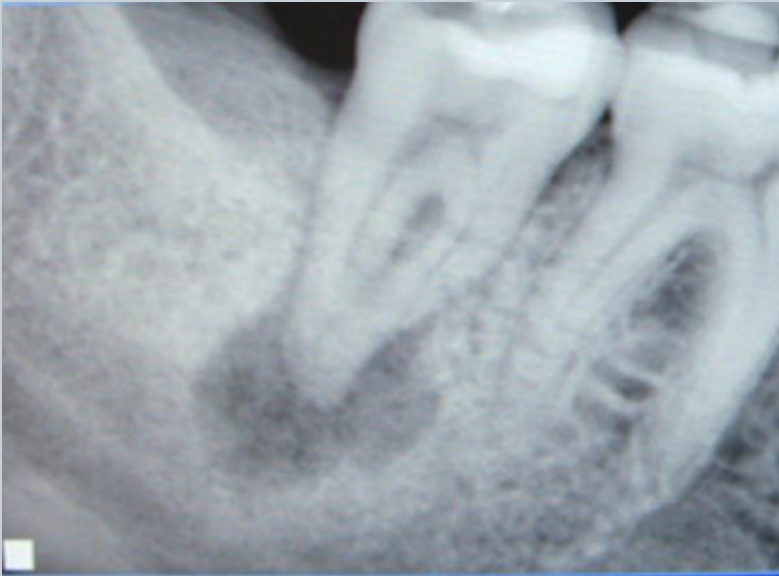
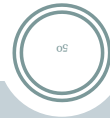
- Not really the best choice.
- Read the slide on infections and try again!

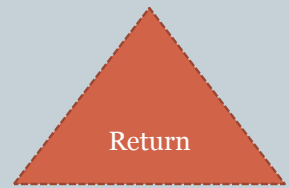
Return

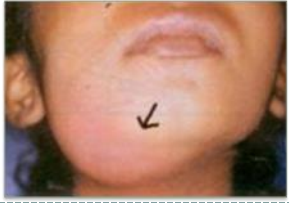

You chose b.

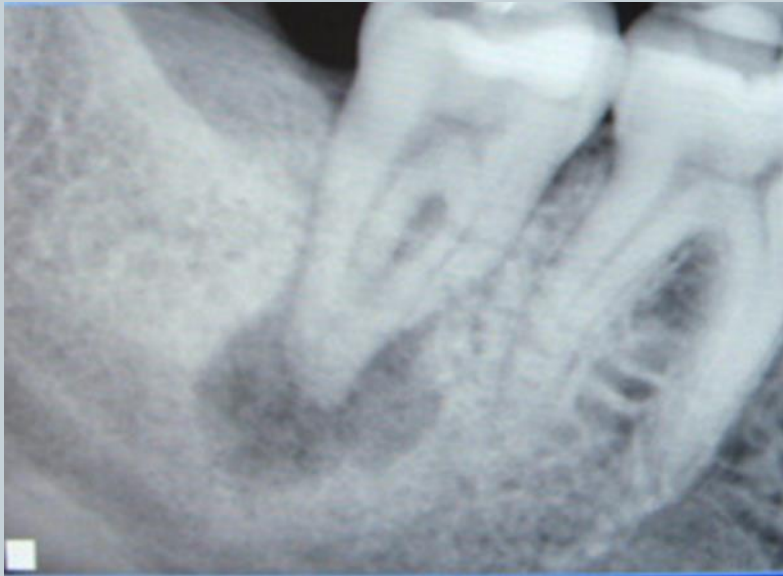

- I&D, delay endo - Correct!
- Of course you want to get the endo done as soon as you can, but generally patients like this will have trouble opening and you will make them much more sore if you try to do it all at once.
- Good job!

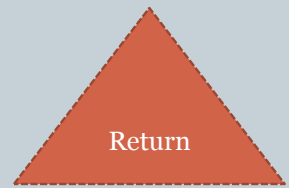




Case 1. You chose c- I&D + Endo



- Not really the best choice.
- Read the slide on infections and try again!



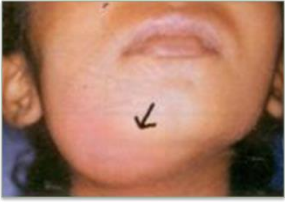

Suzanne: You chose Antibiotics

Not indicated:	Indicated for:
Pulpitis	Persistent infections
Necrotic pulp + radiolucency Apical periodontitis Sinus tract	Systemic illness: Temp >100, Malaise, Lymphadenopathy
Localized, fluctuant swelling (may need to be drained, but still may not need AB's)	Progressive infection: Trismus, Cellulitis, Increasing swelling
"I don't have time to take that tooth out or start a root canal today, so I'll give you this to hold you till I can get you in."	Osteomyelitis (OMFS referral!)
"I'd feel more comfortable if you took some antibiotics"	
The patient wants a prescription for <i>something</i> ...	

- **YES!**
- This is clearly a case for antibiotics. The patient has a fever and a progressing infection.
- Good choice, doctor!
- Keep clicking, though

Return



Suzanne: You chose OTC Pain Meds



- Good idea!
- Not because that is going to be enough for her pain after the I&D surgery (it won't be) but because it is anti-inflammatory. You would give it at the highest dose:
 - 800 mg every 8 hours (tid)
- She will have less overall pain if the inflammation is controlled, not just the pain.
- Keep looking, though



Return



Suzanne: You chose Narcotic Pain Meds



- Of course.
- This woman is going to be in a lot of pain after we open up her neck, drain out a lot of pus, and put in a drain. This is *not* a fun day. Ibuprofen is *not* going to keep her comfortable.
- Patients need narcotics for this sort of pain, and you are wise to prescribe it in advance of the pain.
- Keep looking, though



Return